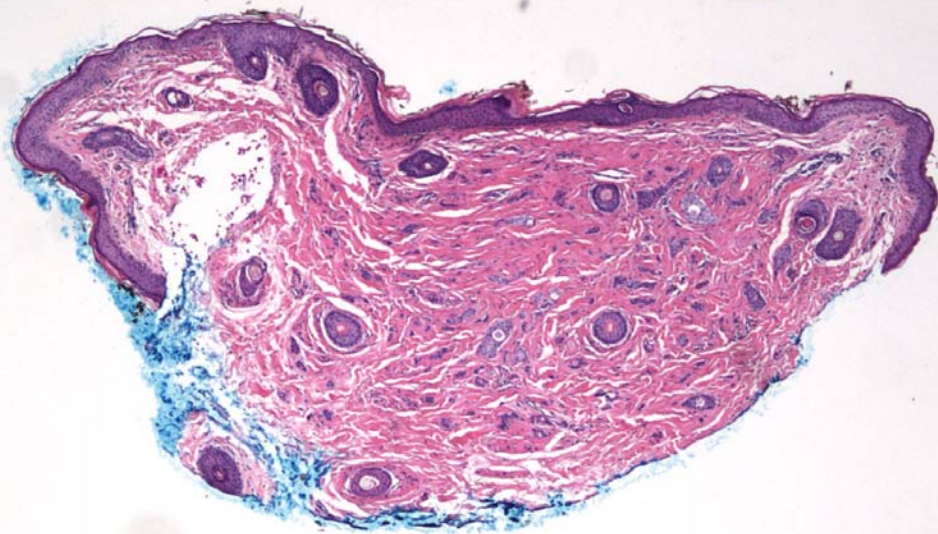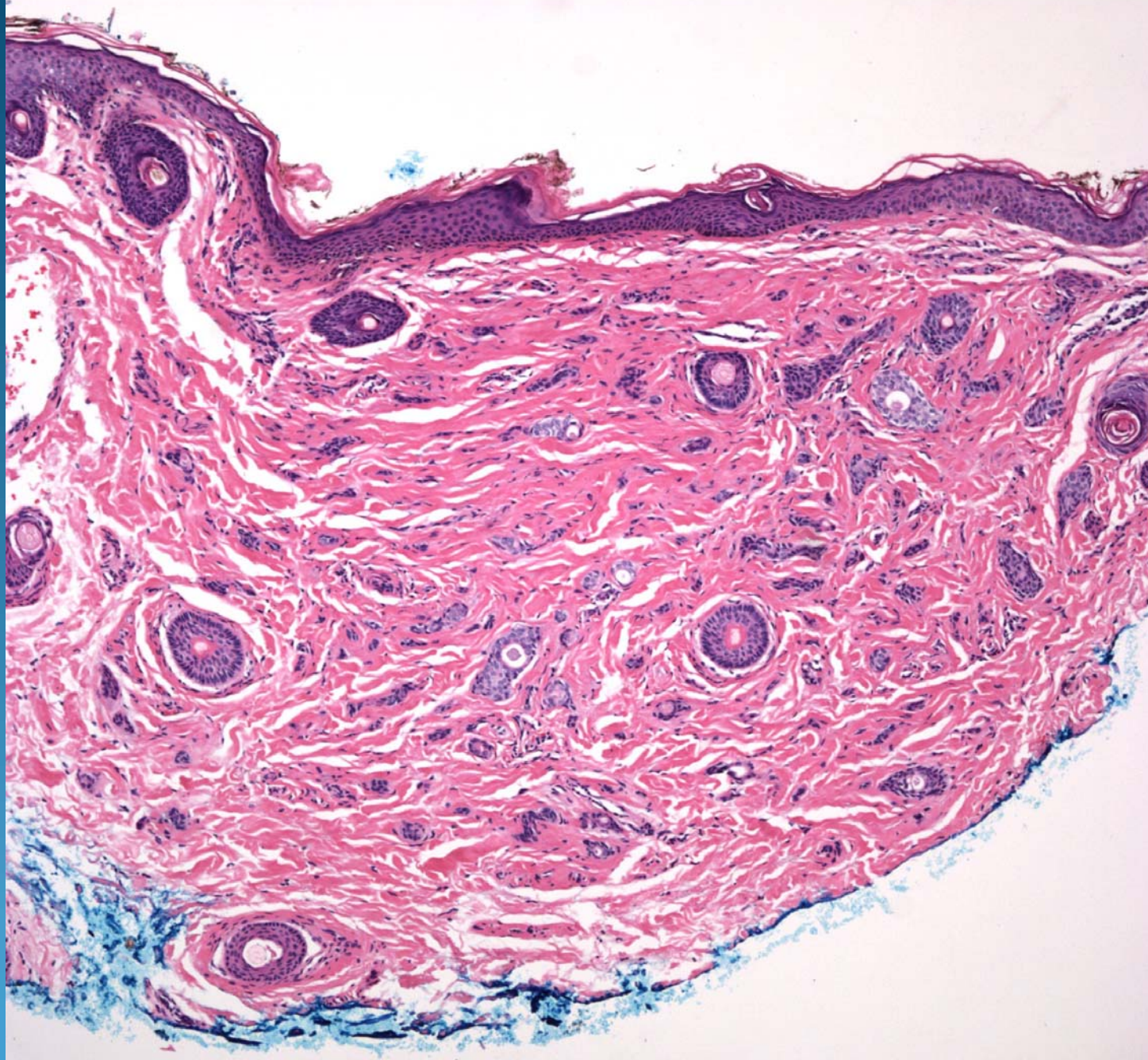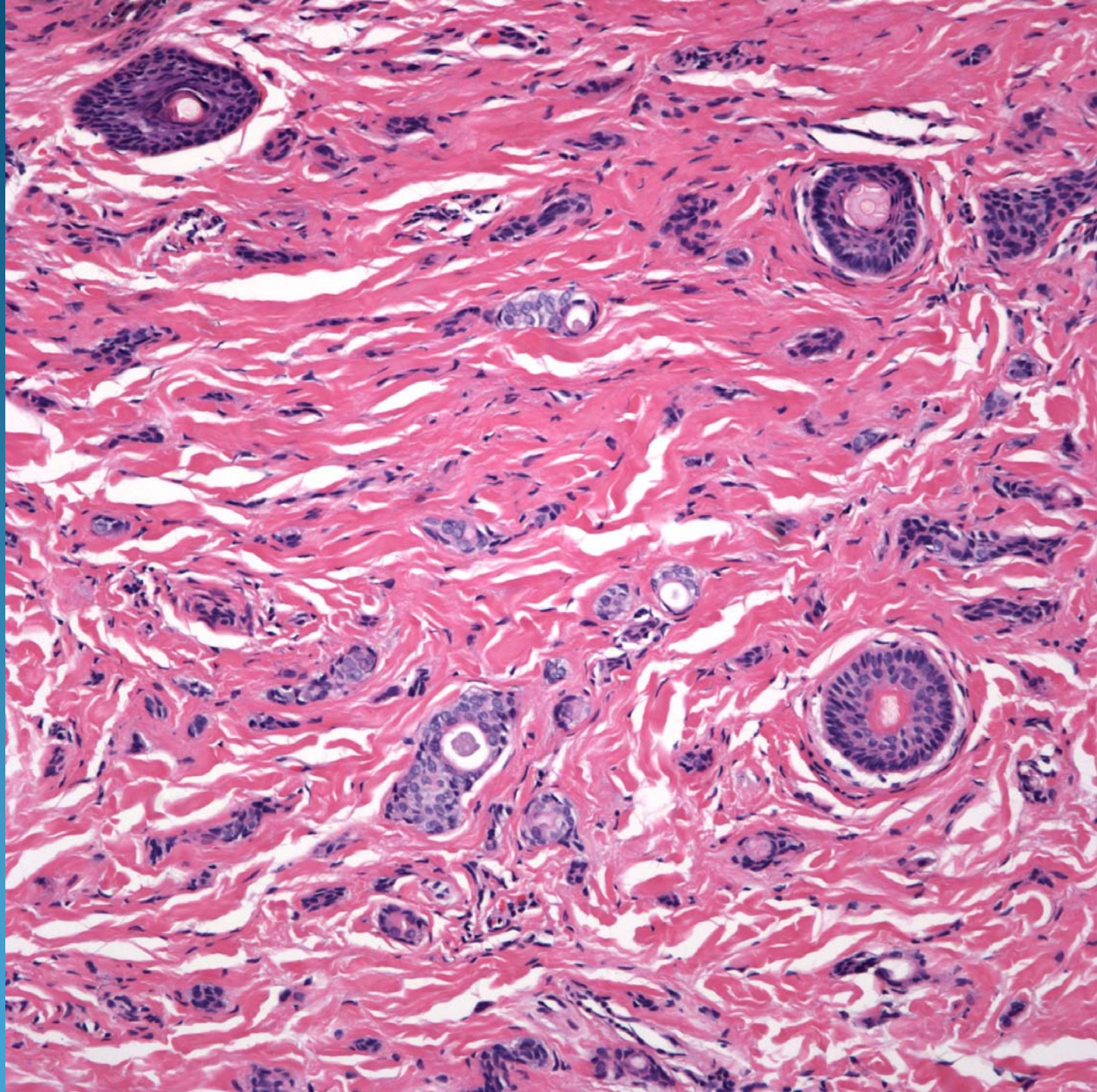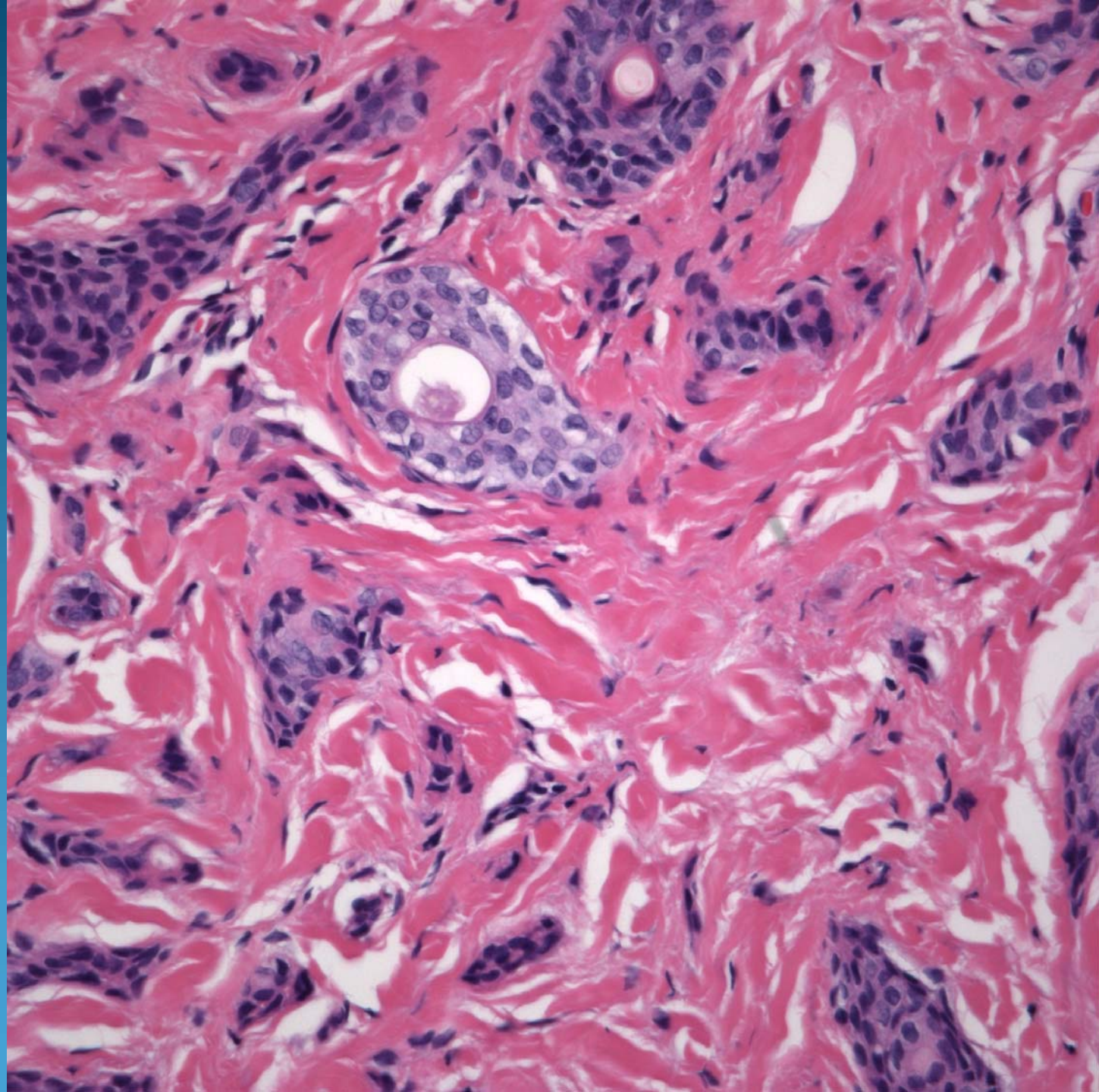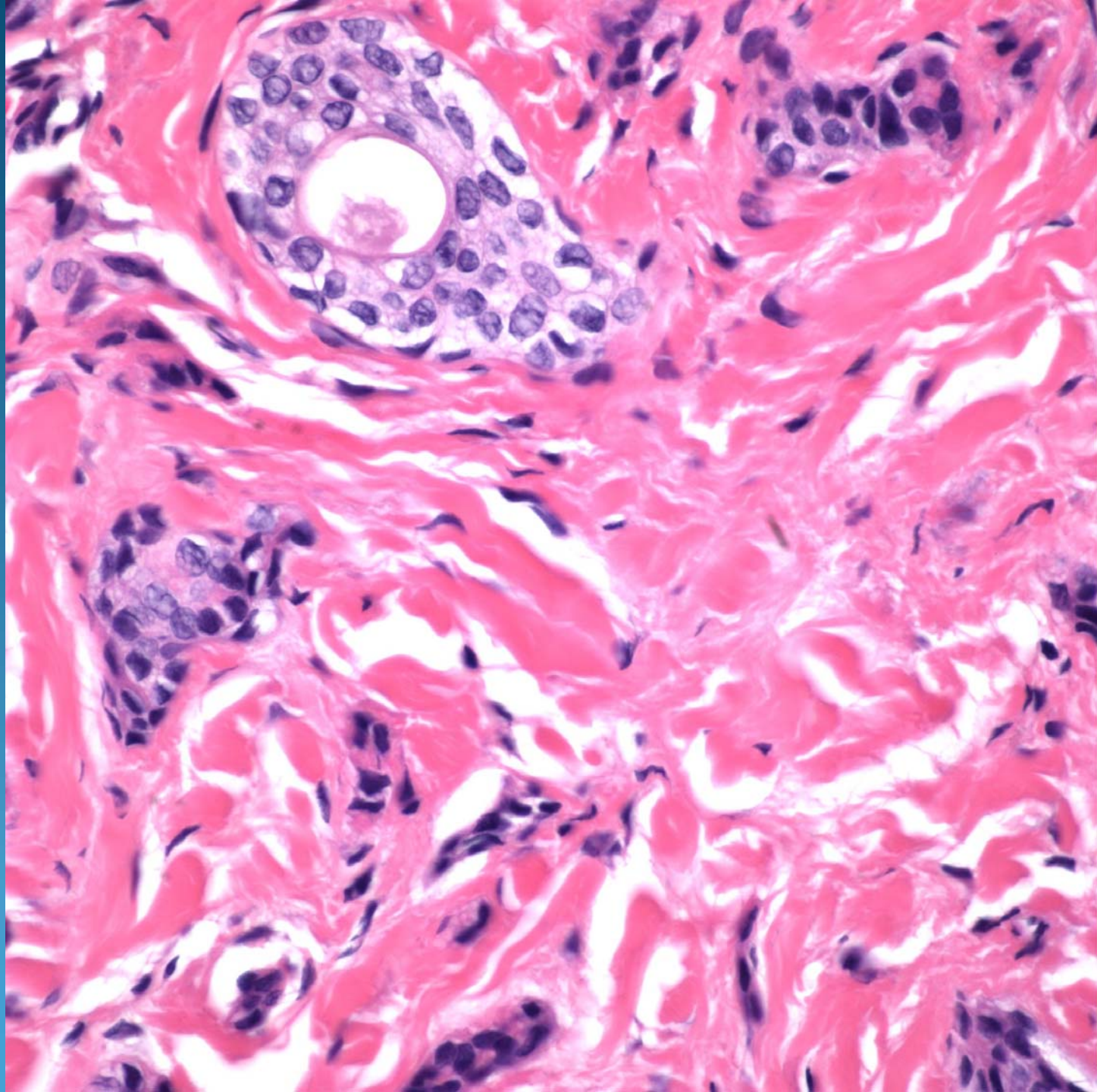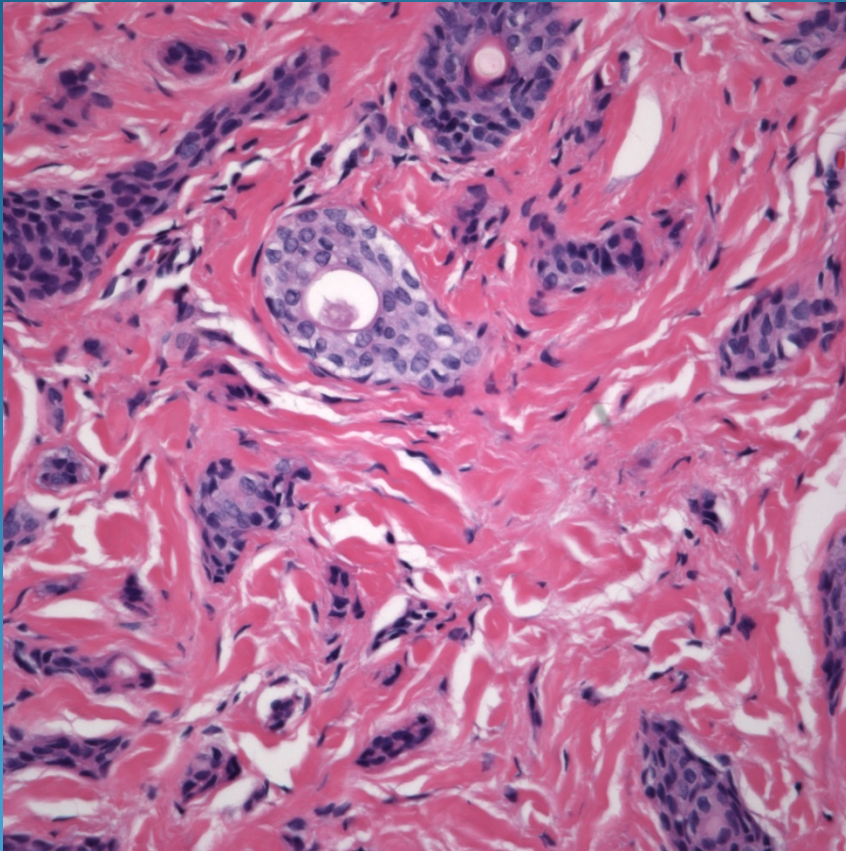


Syringoma

Pearls



- Comma shaped ducts lined by squamous epithelial cells with no atypia
- Sclerotic stroma surrounds the epithelial proliferation
- Correlate with clinical appearance (usually multiple and always superficial)